

See discussions, stats, and author profiles for this publication at: <https://www.researchgate.net/publication/257299927>

Sudden Infant Death Following Hexavalent Vaccination: A Neuropathologic Study

Article in *Current Medicinal Chemistry* · September 2013

DOI: 10.2174/09298673113206660289 · Source: PubMed

CITATIONS

2

READS

529

3 authors, including:



Anna Lavezzi

University of Milan

213 PUBLICATIONS 2,438 CITATIONS

SEE PROFILE

Some of the authors of this publication are also working on these related projects:



sudden perinatal death [View project](#)



TRIVALENT IRON ELIMINATION FROM BLOOD [View project](#)

Sudden Infant Death Following Hexavalent Vaccination: A Neuropathologic Study

L. Maturri¹, G. Del Corno^{1,2} and A.M. Lavezzi^{*1}

¹"Lino Rossi" Research Center for the Study and Prevention of Unexpected Perinatal Death and SIDS - Department of Biomedical, Surgical and Dental Sciences, University of Milan; ²University of Milan Bicocca, Italy

Abstract: We examined a large number of sudden infant death syndrome victims in order to point out a possible causal relationship between a previous hexavalent vaccination and the sudden infant death. We selected 110 cases submitted to in-depth histological examination of the autonomic nervous system and provided with detailed clinical and environmental information. In 13 cases (11.8%) the death occurred in temporal association with administration of the hexavalent vaccine (from 1 to 7 days). In none of these victims congenital developmental alterations of the main nervous structures regulating the vital functions were observed. Only the hypoplasia of the arcuate nucleus was present in 5 cases. In one case in particular an acquired hyperacute encephalitis of the tractus solitarius nucleus was diagnosed in the brainstem. This study does not prove a causal relationship between the hexavalent vaccination and SIDS. However, we hypothesize that vaccine components could have a direct role in sparking off a lethal outcome in vulnerable babies. In conclusion, we sustain the need that deaths occurring in a short space of time after hexavalent vaccination are appropriately investigated and submitted to a post-mortem examination particularly of the autonomic nervous system by an expert pathologist to objectively evaluate the possible causative role of the vaccine in SIDS.

Keywords: Autonomic nervous system, brainstem, hexavalent vaccine, neuropathology, risk factors, SIDS.

INTRODUCTION

During the first year of life, babies receive several immunizations. In particular, hexavalent vaccines protect babies from six infectious diseases: poliomyelitis, diphtheria, tetanus, pertussis, *Haemophilus influenzae* type b and hepatitis B. The rationale to combine these vaccines into one syringe was to reduce the number of injections and thereby to increase the vaccination coverage [1].

In 2000 two hexavalent products were licensed in the European Union (EU) through a centralized license procedure: Hexavac (by Aventis Pasteur MSD) and Infanrix hexa (by Glaxo SmithKline Biologicals). Since licensure, the two vaccines are extensively used in EU countries, with an immunization schedule including three doses at the 3rd, 5th, and 11th/12th month of life. Only in Germany, four administrations are recommended, at the 2nd, 3rd, 4th, and between the 11th and 15th month.

In Italy, that represents the second largest market of Hexavac in the world, no signal of a possible association with the occurrence of sudden infant death syndrome (SIDS) emerged from the pharmacovigilance system report. Also publications addressing the onset of SIDS after hexavalent vaccination in the first year of life [2-9], refuted the causal association between the administration of the vaccine and death. On the

contrary, most of these studies indicated a "protective effect" of vaccination against SIDS [3-7].

Nevertheless, in 2003 a German study gave rise to the suspicion of a possible association between administration of hexavalent vaccines and SIDS [10]. The signal was based on the observation of three deaths which occurred between November 2000 and June 2003 in toddlers in their second year of life (more properly SUD-sudden unexplained death, since SIDS is referred to death in the first year of life) within 48 hrs following the administration of the fourth dose. More recently, again in Germany, Zinka *et al.* [11], in an afterwards much discussed and criticized letter [12-14], reported six cases of SIDS which occurred 1-2 days after the hexavalent vaccine administration.

Therefore, starting from these reports, we decided to re-examine our wide survey of infant deaths, collected on the basis of the Italian law no.31[#], in order to highlight a possible causal relationship between hexavalent vaccination and sudden infant death.

The strength of our analytical approach, compared to others reported in the literature, is that it may be able to

*Address correspondence to this author at the "Lino Rossi" Research Center, Department of Biomedical, Surgical and Dental Sciences, University of Milan, Italy, Via della Commenda, 19 - 20122 Milan, Italy; Tel: +39-02-50320821; Fax: +39-02-50320823; E-mail: anna.lavezzi@unimi.it

[#] The Italian law no.31 (2006) "Regulations for Diagnostic Post Mortem Investigation in Victims of Sudden Infant Death Syndrome (SIDS) and Sudden Intrauterine Unexpected Death (SIUD)" decrees that all infants with suspected SIDS who died suddenly in Italian regions within the first year of age, as well as all fetuses who died after the 25th week of gestation without any apparent cause, must undergo an in-depth anatomopathological examination, particularly of the autonomic nervous system.

determine true cases of SIDS on the basis of the in-depth examination of the autonomic nervous system (ANS) as required by the Italian guidelines.

MATERIAL AND METHODS

Study Subjects

From the large number of victims of sudden infant death (SIDS) (147 cases collected in the 2000/2010 decade), sent to our Research Center according to the guidelines established by the Italian law no.31 [15, 16], we selected 110 cases, aged from 1 to 10 postnatal months. These cases were selected on the basis of completeness of data, namely a detailed histological examination particularly of the ANS, and collection of clinical/environmental information, such as prematurity, sleep position, maternal smoking, maternal drug abuse, type of feeding, etc. In particular, in accordance with the aim of the study, the vaccination history of the victims was documented (type of vaccine, time of vaccination, etc.). The hexavalent vaccines (combined diphtheria, tetanus, pertussis, hepatitis B, poliomyelitis and *Haemophilus influenzae* type b) usually used were the "Hexavac" (Aventis Pasteur MSD) and "Infanrix Hexa" (Glaxo SmithKline Biologicals).

Below we briefly summarize the protocol applied to the study subjects for the examination of the brainstem and cerebellum, where the main structures involved in the control of the vital functions (cardiorespiratory, arousal, upper digestive tract, etc.) are located.

After fixation in 10% phosphate-buffered formalin, the brainstem and cerebellum were processed and paraffin-embedded. Transverse serial sections of the midbrain, pons, medulla oblongata and cerebellar hemispheres were made at intervals of 50-60 μm . For each level, serial 5 μm sections were obtained, three of which were routinely stained for histological examination using hematoxylin-eosin, Klüver-Barrera and Bielschowsky methods and the remaining sections were submitted to specific immunohistochemical techniques for visualization of neurotransmitters (such as somatostatin, serotonin, tyrosine-hydroxylase), apoptosis and gliosis.

The routine histological evaluation of the brainstem was focused on the locus coeruleus and the parabrachial/Kölliker-Fuse complex in the rostral pons/caudal mesencephalon, on the retrotrapezoid nucleus, the superior olivary complex and the facial/parafacial complex in the caudal pons; on the hypoglossus, the dorsal motor vagal, the tractus solitarius, the ambiguus, the pre-Bötzinger, the inferior olivary, the raphé and the arcuate nuclei in the medulla oblongata. In the cerebellum, the cortex layers (external granular layer, molecular layer, Purkinje cell layer and internal granular layer) and the medullary deep nuclei (the dentate nucleus, the fastigial nucleus, the globose nucleus and the emboliform nucleus) were examined.

A more detailed description of the histological procedures and the localization of the structures subjected to the microscopic examination can be found in our previous publications [15-21].

Ethics - Ethics approval for this study was granted by the Italian Health's Ministry in accordance with the above-mentioned Italian law no. 31.

RESULTS

From the thorough analysis of our series of infants who died suddenly (110 cases), we extracted 13 victims of SIDS (11.8%), 6 females and 7 males aged from 2 to 10 months, died in temporal association with the inoculation of hexavalent vaccine, without specific clinical symptoms. Only in 2 cases slight fever and diarrhea episodes were reported within two days after the first dose of the vaccine.

Most of these babies died at 2-3 months of life (8/13), shortly after the first dose of the vaccine (precisely 6 cases within the first three days and 2 cases in fifth and sixth day, respectively). In 4 cases, aged 4-5 months, the death occurred within 3 days from the second dose of vaccine and in 1 case, 10 months old, one week after the third administration.

The examination of other circumstances and potential risk factors, such as maternal smoking and prematurity, did not provide any relevant information. In fact, all 13 infants were born at more than 37 weeks' gestation with a birth weight >2,500 g, and all mothers declared no history of cigarette smoking.

The in-depth examination of the ANS, particularly of the brainstem and cerebellum in serial histological sections, revealed aspecific findings such as brain edema and congestion in all the victims. In no case we observed congenital developmental alterations of the main ANS structures that control vital functions, with the exception of the hypoplasia of the arcuate nucleus in the medulla oblongata (a very frequent defect observable in both victims of sudden death and controls) found in 6 cases. These results allowed to formulate a diagnosis of true "SIDS" (Sudden Infant Death Syndrome) in 12 of the 13 victims.

In one case, a 3 month-old male, the only neuropathological finding was represented by an acquired hyperacute encephalitis of the tractus solitarius nucleus, viral in nature, as indicated by the presence of necrosis, degeneration of myelin-sheaths and breaking of nerve fibers, without inflammatory cells and astrocytes (Fig. 1). This death cannot be classified as unexplained, but more precisely as "borderline". Table 1 summarizes all the data related to the 13 cases with a recent history of hexavalent vaccine administration.

DISCUSSION

The acceptance of vaccinations by population is essential to control vaccine-preventable diseases; in particular, hexavalent vaccines allow babies a primary immunization with the simultaneous administration in a single injection of six vaccines containing antigens to immunize against diphtheria, tetanus, pertussis, poliomyelitis, hepatitis B and *Haemophilus influenzae* type b [22].

The advantage of this type of immunization, in that reducing the number of injections represents a good solution to parental concerns, has nonetheless given rise to the need to study the risk of adverse events associated with simultaneous administration of multiple antigens [23, 24]. In particular, the association between vaccinations and SIDS has been frequently investigated, but most of the studies rejected any causal relationship [2-9].

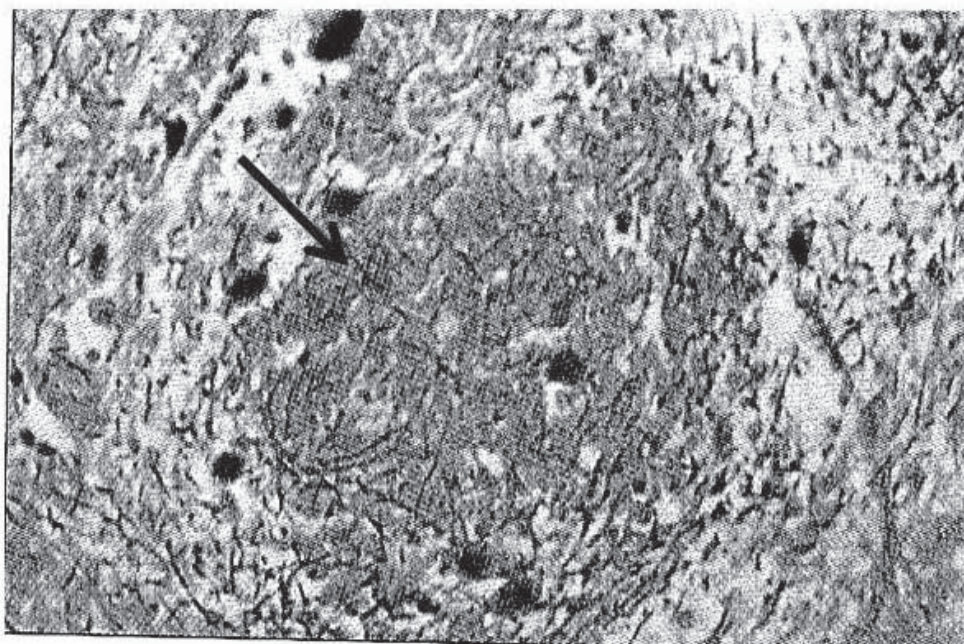


Fig. (1). Case no.11. Necrotic focus (see arrow) with degeneration of myelin-sheaths and nerve fibers in the tractus solitarii nucleus. Bielschowsky method, magnification 400x.

Table 1. Features of the 13 Infants Suddenly Died in Temporal Association with Hexavalent Vaccination: Correlation with Autonomic Nervous System Findings, Prematurity and Maternal Smoking

Case No.	Age at Death (Months)	Sex	Prematurity	Time Since Vaccination (Days)			Maternal Smoking	Neuropathologic Findings
				1 st dose	2 nd dose	3 rd dose		
1	2	F	-	2			-	Arcuate nucleus hypoplasia
2	3	F	-	1			-	Arcuate nucleus hypoplasia
3	3	F	-	6			-	-
4	3	M	-	3			-	-
5	5	F	-		3		-	-
6	3	M	-	1			-	Arcuate nucleus hypoplasia
7	3	M	-	2			-	Arcuate nucleus hypoplasia
8	3	M	-	5			-	Arcuate nucleus hypoplasia
9	10	F	-			7	-	-
10	4	M	-		2		-	-
11	3	M	-	3			-	Hyperacute encephalitis tractus solitarii nucleus
12	5	M	-		3		-	-
13	5	F	-		3		-	Arcuate nucleus hypoplasia

In Europe, the European Medicines Agency (EMA) commissioned in 2003 a Committee for Medicinal Products for Human Use (CHMP), constituted by a panel of police doctors, cardiologists and neuro-pathologists to investigate five cases of SIDS which occurred in Germany within 24 hrs from inoculation of hexavalent vaccines and to discuss in a multidisciplinary meeting the plausible link between immu-

nization and infant death. The experts concluded that a direct etiologic relationship between vaccination and death cannot be proven. Thus, despite of the possibility that SIDS may be triggered in rare instances after hexavalent vaccination, the EMA declared that no regulatory action was necessary concerning this type of immunization [25].

Nevertheless, the same CHMP, in a subsequent meeting in 2005, after the identification of a decreased immunogenicity (the ability to stimulate an immune response) of the hepatitis B component, recommended, as a precautionary measure, the suspension of the marketing authorization for the "Hexavac" vaccine [26]. Currently, with the support of the German Health Survey for Children and Adolescents [27], the use of this vaccine is suspended in all the European Union [28]. Moreover, in March 2011, Japan's Health Ministry ordered doctors to stop immunizing infants with hexavalent vaccines in relation to the sudden death of five babies within a short period of time after its administration [29].

The definition of "SIDS" reported in literature for sudden infant deaths after hexavalent vaccination is rather questionable, since in such cases a post-mortem examination is not routinely performed or alternatively, it is performed in a superficial way, without an in-depth study of the ANS. An example is the work of Von Kries *et al.* [10]. These authors reported as neuropathological findings after the autopsy investigation only brain edema, presence of cytotoxic neurons and rare inflammatory cells, without examining the vital centers of the brainstem.

We strongly sustain that only a deep examination in serial histological sections of the ANS, particularly of the brainstem where the main vital centers are located, allows to formulate a diagnosis of SIDS. In 2002 we formulated a precise definition of SIDS as "the sudden death of an infant under one year of age which remains unexplained after a thorough investigation of the case, including the performance of a complete autopsy with in-depth histological examination of the autonomic nervous system only by an experienced, reliable pathologist" [30]. Thus, in the absence of this in-depth examination, we maintain that the reports of the Italian Health Institute on SIDS mortality, based on the death certificates collected by the Italian National Institute of Statistics (approximately 0.6 deaths per 10,000 newborns) are unreliable.

Recently we published a study performed on a very large sample of fetal and infant deaths (313 victims including 95 unexpected perinatal deaths, 140 SIDS and 78 controls) [31], in which one or more congenital ANS abnormalities were found in 90% of SIDS victims. The presence of a subgroup of infant deaths without developmental neuronal defects has been confirmed in the present study on 110 SIDS victims selected on the basis of the completeness of the anamnestic, clinical, environmental and neuropathological data. In particular, the 13 cases who suddenly died in temporal association with administration of hexavalent vaccines were characterized by the absence of congenital alterations of the nervous vital centers. The only developmental alteration was the hypoplasia of the arcuate nucleus that we considered a poorly significant finding, given that it is frequently present in control subjects who died from known causes. Similarly, specific findings such as edema and congestion were observed in both controls and SIDS cases and were apparently unrelated to vaccination.

The acquired alteration of encephalitic type of the tractus solitarius nucleus observed in one case was noteworthy. The main histological findings were necrosis, absence of inflam-

matory cells and loss of astrocytes and myelinated fibers. A similar pattern of histological abnormalities was reported by Drobysky *et al.* [32] in two distinct regions of the cerebral cortex in a patient subjected to allogenic bone transplantation for relapsed Hodgkin's disease. These authors diagnosed an encephalitis limited to these areas and demonstrated, by immunohistochemical and molecular techniques, the direct implication of the human herpes virus-6 (HHV-6) as etiologic agent.

Of additional relevance, Aydin *et al.* [33] reported a case of acute necrotizing encephalopathy (ANE) involving thalamus, brainstem and cerebellum and secondary to vaccination with diphtheria, tetanus toxoid and pertussis booster. Neuropathologically, ANE lesions are characterized by oedema, petechial haemorrhage and necrosis, thus suggesting a local breakdown of the blood brain barrier (BBB). In this context, Aydin *et al.* suggest [33] that the breakdown of the BBB may occur due to pro-inflammatory cytokine release by the glial macrophages which can be stimulated either by viral infection or vaccination. Indeed, in a comprehensive study on ANE, Mizuguchi [34] showed in more than 50 cases through MRI and computed tomography (CT) ANE lesions in both the gray and white matter, with neuropathological evidence of a local breakdown of the BBB. It was speculated that in these cases viral infections were involved. In summary, in the case here examined, we can hypothesize either a vaccine or viral involvement in triggering the tractus solitarius nucleus necrotizing encephalitis (characterized by extensive necrosis, breaking of nerve fibers and loss of myelinated fibers, in the absence of inflammatory cell infiltrates). This lesion could imply a glossopharyngeal-vagal activation, with consequent fatal compromising of breathing, heart activity and upper digestive tract kinetics.

In summary, our report does not prove a causal relationship between hexavalent vaccination and SIDS. Despite the limitation of our observations, it is likely that the mechanism of death after hexavalent vaccination cannot be attributed to particularly significant brain abnormalities. We can however suppose a direct role of vaccine components in triggering a lethal outcome in a vulnerable baby. We know in fact that many infants are vaccinated but not everyone dies or has an adverse reaction following vaccination. Hence clearly, there are both specific genetic and constitutional factors of susceptibility which could define how one reacts to a vaccine. In particular, we hypothesize that several compounds and immunopotential adjuvants of the hexavalent vaccine might easily go beyond the BBB, that in the first months of life is still immature and quite permeable [35], inducing neuronal molecular alterations in DNA, RNA, and proteins of brainstem neurons regulating vital functions, with consequent fatal disorganization of respiratory control in particularly predisposed infants. Notably, the neurotoxicity of the aluminium adjuvant in vaccine-relevant exposures has been experimentally demonstrated, including its ability to cross the BBB and induce inflammatory and neurodegenerative changes [36-38].

In conclusion, the present work constitutes a basis for intensifying surveillance after the hexavalent vaccination. In particular, it is necessary that deaths occurring short time after hexavalent vaccination are appropriately investigated

and submitted to an expert pathologist for an objective evaluation of the possible causative role of vaccines in SIDS.

CONFLICT OF INTEREST

All authors declare that they have no financial or other conflicts of interests.

ACKNOWLEDGEMENTS

This study was supported by the Italian Health's Ministry in accordance with the Italian law no.31 (2006) "Regulations for Diagnostic Post Mortem Investigation in Victims of Sudden Infant Death Syndrome (SIDS) and Sudden Intrauterine Unexpected Death (SIUD)".

REFERENCES

- Schmitt, H.J.; von Kries, R.; Hassenpflug, B.; Hermann, M.; Siedler, A.; Niessing, W. *Haemophilus influenzae* type b disease: impact and effectiveness of diphtheria-tetanus toxoids-acellular pertussis (-inactivated poliovirus)/ *H. influenzae* type b combination vaccines. *Pediatr. Infect. Dis. J.*, **2001**, *20*, 767-774.
- Bouvier-Colle, M.H.; Flahaut, A.; Messiah, A.; Jouglu, E.; Hatton, F. Sudden infant death and immunization: an extensive epidemiological approach to the problem in France-winter 1986. *Int. J. Epidemiol.*, **1989**, *18*, 121-126.
- Fleming, P.J.; Blair, P.S.; Platt, M.W.; Tripp, J.; Smith, I.J.; Golding, J. The UK accelerated immunisation programme and sudden unexpected death in infancy: case-control study. *BMJ.*, **2001**, *322*, 1-5.
- Griffin, M.R.; Ray, W.A.; Livengood, J.R.; Schaffner, W. Risk of sudden infant death syndrome after immunization with the diphtheria-tetanus-pertussis vaccine. *N. Engl. J. Med.*, **1988**, *319*, 618-623.
- Mitchell, E.A.; Stewart, A.W.; Clements, M. Immunisation and the sudden infant death syndrome. New Zealand Cot Death Study Group. *Arch. Dis. Child.*, **1995**, *73*, 498-501.
- Roberts, S.C. Vaccination and cot deaths in perspective. *Arch. Dis. Child.*, **1987**, *62*, 754-759.
- Hoffman, H.J.; Hunter, J.C.; Damus, K.; Pakter, J.; Peterson, D.R.; van Belle, G. Diphtheria-tetanus-pertussis immunization and sudden infant death: results of the National Institute of Child Health and Human Development Cooperative Epidemiological Study of Sudden Infant Death Syndrome risk factors. *Pediatrics*, **1987**, *79*, 598-611.
- Jonville-Bera, A.P.; Autret-Leca, E.; Laugier, J. Sudden infant deaths syndrome and diphtheria-tetanus-pertussis-poliomyelitis vaccination status. *Fundam. Clin. Pharmacol.*, **1995**, *9*, 263-270.
- Jonville-Bera, A.P.; Autret-Leca, E.; Barbeillon, F.; Paris-Llado, J. Sudden unexpected death in infants under 3 months of age and vaccination status-a case-control study. *Br. J. Clin. Pharmacol.*, **2001**, *51*, 271-276.
- Von Kries, R.; Toschke, A.M.; Strassburger, K.; Kundi, M.; Kalies, H. Sudden and unexpected deaths after the administration of hexavalent vaccines (diphtheria, tetanus, pertussis, poliomyelitis, hepatitis B, *Haemophilus influenzae* type b): is there a signal? *Eur. J. Pediatr.*, **2005**, *164*, 61-69.
- Zinka, B.; Rauch, E.; Buettner, A.; Ruëff, F.; Penning, R. Unexplained cases of sudden infant death shortly after hexavalent vaccination. *Vaccine*, **2006**, *24*, 5779-5780.
- Von Kries, R. Comment on B. Zinka et al. Unexplained cases of sudden infant death shortly after hexavalent vaccination. *Vaccine*, **2006**, *24*, 5783-5784.
- Schmitt, H.J.; Siegrist, C.A.; Salmaso, S.; Law, B.; Booy, R. B.; Zinka, B. Unexplained cases of sudden infant death shortly after hexavalent vaccination. *Vaccine*, **2006**, *24*, 5781-5782.
- Maurer, W. Death following hexavalent vaccination. *Vaccine*, **2005**, *23*, 5461-5463.
- Matturri, L.; Ottaviani, G.; Lavezzi, A.M. Techniques and criteria in pathologic and forensic-medical diagnostics of sudden unexpected infant and perinatal death. *Am. J. Clin. Pathol.*, **2005**, *124*, 259-268.
- Matturri, L.; Ottaviani, G.; Lavezzi, A.M. Guidelines for neuropathologic diagnostics of perinatal unexpected loss and sudden infant death syndrome (SIDS). A technical protocol. *Virchows Arch.*, **2008**, *452*, 19-25.
- Lavezzi, A.M.; Ottaviani, G.; Ballabio, G.M.; Rossi, L.; Matturri, L. Preliminary study on the cytoarchitecture of the human parabrachial/Kölliker-Fuse complex with reference to sudden infant death syndrome and sudden intrauterine unexplained death. *Pediatr. Dev. Pathol.*, **2004**, *72*, 171-179.
- Lavezzi, A.M.; Matturri, L. Functional neuroanatomy of the human pre-Bötzing complex with particular reference to sudden unexplained perinatal and infant death. *Neuropathology*, **2008**, *28*, 10-16.
- Lavezzi, A.M.; Matturri, L. Hypoplasia of the parafacial/facial complex: a very frequent finding in sudden unexplained fetal death. *Open Neurosci. J.*, **2008**, *2*, 1-5.
- Lavezzi, A.M.; Ottaviani, G.; Mauri, M.; Matturri, L. Alterations of biological features of the cerebellum in sudden perinatal and infant death. *Curr. Mol. Med.*, **2006**, *6*, 429-435.
- Lavezzi, A.M.; Ottaviani, G.; Mauri, M.; Matturri, L. Biopathology of the olivocerebellar network in sudden unexplained perinatal and sudden infant death syndrome related to maternal cigarette smoking. *Neurol. Res.*, **2007**, *29*, 525-532.
- Halsey, N.A. Practical considerations regarding the impact on immunization schedules of the introduction of new combined vaccines. *Ann. N. Y. Acad. Sci.*, **1995**, *754*, 250-254.
- Fine, P.E. Methodological issues in the evaluation and monitoring of vaccine safety. *Ann. N. Y. Acad. Sci.*, **1995**, *754*, 300-308.
- Chen, R.T.; Pool, V.; Takahashi, H.; Weniger, B.G.; Patel, B. Combination vaccines: postlicensure safety evaluation. *Clin. Infect. Dis.*, **2001**, *33* (Suppl 4), S327-S333.
- European Medicine Agency (EMA). Update on hexavalent vaccines: Hexavac and Infanrix Hexa. http://www.emea.europa.eu/docs/en_GB/document_library/Public_statement/2010/01/WC500059303.pdf (Accessed December 1, 2003).
- European Medicines Agency (EMA). Questions and answers on the suspension of Hexavac, 2005, London, United Kingdom (<http://www.ema.europa.eu/humandocs/PDFs/EPAR/Hexavac/30488805en.pdf>). (Accessed 26 June 26, 2009).
- Jorgensen, P.; Poethko-Müller, C.; Hellenbrand, W.; Jilg, W.; Thierfelder, W.; Meyer, C.; der Heiden, M.; Schlaud, M.; Radun, D. Low hepatitis B immunogenicity of a hexavalent vaccine widely used in Germany: results of the German Health Survey for Children and Adolescents, 2003-2006. *Epidemiol. Infect.*, **2010**, *138*, 1621-1629.
- European Medicines Agency (EMA). Scientific conclusions and grounds for the suspension of the marketing authorization of Hexavac presented by the EMA, 2005. <http://www.emea.europa.eu/humandocs/PDFs/EPAR/Hexavac/Hexavac-H-298-Z-28-en.pdf>. (Accessed April 13, 2010).
- Lah, K. Japan suspends 2 vaccines while authorities investigate infant deaths. From CNN. <http://edition.cnn.com/2011/HEALTH/03/08/japan.vaccines/index.html> (Accessed March 8, 2011).
- Matturri, L.; Lavezzi, A.M.; Rossi, L. Proposal to modify the definition of SIDS, with regard to the post-mortem exam. In: *Proceedings 7th Int Conference on SIDS, Florence 2002*, p.103.
- Matturri, L.; Lavezzi, A.M. Unexplained stillbirth versus SIDS: common congenital diseases of the autonomic nervous system - Pathology and nosology. *Early Hum. Dev.*, **2011**, *87*, 209-215.
- Drobyski, W.; Knox, K.; Majewski, D.; Carrigan, D. Brief report. Fatal encephalitis due to variant B human herpesvirus-6 infection in a bone marrow-transplant recipient. *N. Engl. J. Med.*, **1994**, *330*, 1356-1360.
- Aydin, H.; Ozgul, E.; Agildere, A.M. Acute necrotizing encephalopathy secondary to diphtheria, tetanus toxoid and whole-cell pertussis vaccination: diffusion-weighted imaging and proton MR spectroscopy findings. *Pediatr. Radiol.*, **2010**, *40*, 1281-1284.
- Mizuguchi, M. Acute necrotizing encephalopathy of childhood: a novel form of acute encephalopathy prevalent in Japan and Taiwan. *Brain Dev.*, **1997**, *19*, 81-92.
- Zheng, W. Neurotoxicology of the brain barrier system: new implications. *Toxicol. Clin. Toxicol.*, **2001**, *39*, 711-719.
- Khan, Z.; Combadiere, C.; Authier, F.J.; Itier, V.; Lux, F.; Exley, C.; Mahrouf-Yorgov, M.; Decrouy, X.; Moretto, P.; Tillement, O.; Gherardi, R.K.; Cadusseau, J. Slow CCL2-dependent translocation of biopersistent particles from muscle to brain. *BMC. Med.*, **2013**, *11*: 99.

- [37] Lujan, L.; Perez, M.; Salazar, E.; Alvarez, N.; Gimeno, M.; Pinczowski, P.; Irusta, S.; Santamaria, J.; Insausti, N.; Cortes, Y.; Figueras, L.; Cuartielles, I.; Vila, M.; Fantova, E.; Chapulle, J.L. Autoimmune/autoinflammatory syndrome induced by adjuvants (ASIA syndrome) in commercial sheep. *Immunol. Res.*, **2013**, doi: 10.1007/s12026-013-8404-0 [Epub ahead of print].
- [38] Shaw, C.A.; Petrik, M.S. Aluminum hydroxide injections lead to motor deficits and motor neuron degeneration. *J. Inorg. Biochem.*, **2009**, *103*(11), 1555-1562.

Received: January 08, 2013 Revised: February 05, 2013 Accepted: September 18, 2013